

Case 1591: Pituitary stalk interruption syndrome: magnetic resonance findings

Subspecialty: Neuroradiology
Date of Publication: 2002.07.09

G. Zuccoli, F. Nicoli, G. Tognini, F. Ferrozzi.
Arcispedale Santa Maria Nuova
42100 - Reggio Emilia / ITALY

Patient:

Age: 10 year(s)
Sex: female

Clinical Summary

The patient was referred because of short stature. She was found to have severe isolated growth hormone deficiency. A magnetic resonance study of the hypothalamo-hypophyseal axis was performed.

Clinical History and Imaging Procedures

The patient was referred because of short stature. She was born at term by normal vaginal delivery after an uneventful pregnancy. At presentation her height was below the 3rd percentile for age. Skeletal development was delayed by 2.5 years with respect to her chronological age. Testing was carried out to evaluate hormonal secretion. The patient was found to have severe isolated growth hormone (GH) deficiency (peak GH, 0.33ng/ml; normal, >10ng/ml). At the same time a magnetic resonance (MR) study of the hypothalamo-hypophyseal axis was performed. The sella appeared to be diminished in size and the adenohypophysis to be hypoplastic. The posterior neurohypophyseal hyperintense signal (also called the "bright spot") was not found within the sella in any section performed. The stalk appeared to be interrupted. At the median eminence level a small bright spot was identified on T1-weighted sagittal and coronal images (Figs 1 and 2).

Discussion

The neurohypophysis is composed of three parts: the lobe, the posterior portion of the pituitary stalk and the median eminence. The sella turcica cavity contains the posterior neural lobe and a small part of the stalk. The neurohypophysis does not produce hormones. Antidiuretic hormone and oxytocin are produced in the nuclei of the hypothalamus and, flowing along the stalk, are released in the neural lobe by exocytosis. The posterior lobe functions like a store and releases its contents as a consequence of neurohypophyseal stimuli. Hypothalamo-hypophyseal axis abnormalities are frequently associated with pituitary deficiency. About 40% of patients with idiopathic growth hormone deficient-dwarfism show at the MR examination anomalies of the hypothalamo-hypophyseal axis summarised as follows: ectopia of the posterior neurohypophyseal "bright spot" at the level of the median eminence or at the pituitary stalk level, absence of the hyperintense posterior lobe within the sella turcica, and stalk absence or thinning of the stalk ("pituitary stalk interruption syndrome":PSIS).The chemical origin of the neurohypophyseal hyperintense signal on T1-weighted images is still under debate. It has been found that phospholipid acts as a relaxation enhancer of water protons. For this reason MR characteristics of the neurohypophyseal phospholipid vesicles can account for the observed MR signal intensity. Neurohypophysis on site presence should be considered as an index of normality since it is constantly found in healthy subjects. The origin of the PSIS is also discussed. To date the genetic theory remains the most creditable versus the post-traumatic theory. The absence of normal inductive events in the rostro-medial neural fold has been suggested as a possible explanation for MR abnormalities. PSIS patients are likely to have a severe isolated GH deficiency or multiple hormonal deficiencies with lower GH levels. MR examination of children with less severe hormonal deficiencies frequently shows a normal or a small pituitary gland.

Final Diagnosis

Pituitary stalk interruption syndrome (PSIS) associated with growth hormone deficient-dwarfism

Figure 1: T1-weighted sagittal image

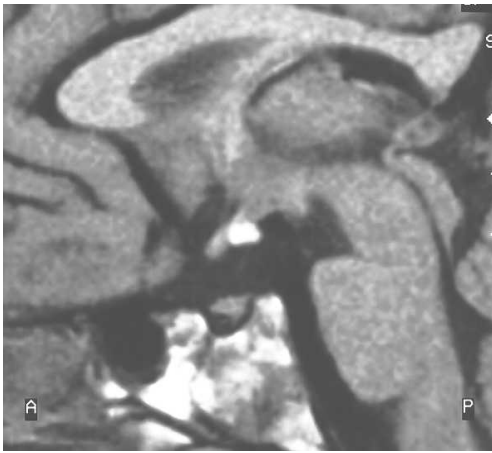


Figure 1a

The sagittal T1-weighted MR image shows a "bright spot" at the median eminence level. The pituitary posterior lobe hyperintense signal is absent within the sella turcica cavity. The stalk appears to be interrupted.

Figure 2: T1-weighted coronal image

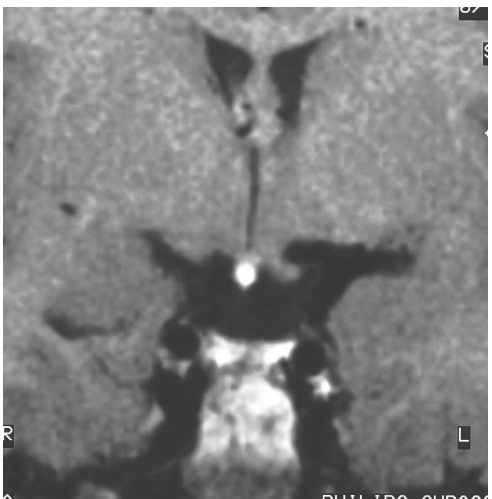


Figure 2a

This coronal T1-weighted image confirms the presence of the ectopic posterior pituitary "bright spot" at the median eminence level.

MeSH:

[C10.228.140.617.738] Pituitary Diseases

Disorders of the anterior or posterior pituitary gland which usually manifest as hypersecretion or hyposecretion of pituitary hormones. Pituitary mass lesions may also produce compression of the OPTIC CHIASM and other adjacent structures.

References:

[1] Elster AD. Modern imaging of the pituitary. *Radiology*. 1993 Apr;187(1):1-14.

[2] Triulzi F, Scotti G, di Natale B, Pellini C, Lukezic M, Scognamiglio M, Chiumello G. Evidence of a congenital midline brain anomaly in pituitary dwarfs: a magneticresonance imaging study in 101 patients. *Pediatrics*. 1994 Mar;93(3):409-16.

[3] Kucharczyk W, Lenkinski RE, Kucharczyk J, Henkelman RM. The effect of phospholipid vesicles on the NMR relaxation of water: an explanation for the MR appearance of the neurohypophysis? *AJNR Am J Neuroradiol*. 1990 Jul-Aug;11(4):693-700.

Citation:

G. Zuccoli, F. Nicoli, G. Tognini, F. Ferrozzi. (2002.07.09)

Pituitary stalk interruption syndrome: magnetic resonance findings, {Online}

URL: <http://www.eurorad.org/case.php?id=1591>